

Review Article

Foam Sclerotherapy versus surgery in treatment of chronic venous disease

Fatih Islamoglu*

Department of Cardiovascular Surgery, Medical Faculty, Ege University, İzmir, Turkey

Abstract

Although the classical surgical treatment methods of chronic venous insufficiency are successful to relieve perfectly the cause (reflux) and result (varicose veins), the new ablation techniques such as endogenous laser ablation therapy (EVLT), radiofrequency (RF) and foam ablation come into currency more and more with their advantage of being performed with only local anesthesia. However, these techniques, still have the potential for residual saphenofemoral reflux due to incomplete ablation of all side branches of the saphenofemoral junction. As an alternative technique ligation + foam sclerotherapy is not only comfortable like EVLT or RF but also safe and effective as much as classic stripping.

The classical surgical treatment methods of chronic venous insufficiency (CVI) are high ligation (HL) and stripping of the saphenous varicose veins, and percutaneous phlebectomy [1,2]. Both the classical methods and the newer ones directed to relieve the cause (reflux) and result (varicose veins). The prevention of the recurrence necessitates the treatment of reflux before the varicosities [3,4]. Although the elimination of reflux is possible with surgery, the new ablation techniques such as endovenous laser ablation therapy (EVLT), radiofrequency (RF) and foam ablation come into currency more and more with their advantage of being performed with only local anesthesia. However, these techniques, still have the potential for residual saphenofemoral reflux due to incomplete ablation of all side branches of the saphenofemoral junction (SFJ) [3,4]. All newer thermal ablation techniques cannot obliterate completely the side branches draining to the SFJ which is possible with HL and surgery. Although the classical surgical HL has also been blamed to lead to recurrent varicose vein development due to neovascularization, it is shown that real neovascularization demonstrated by Doppler is rare and is mostly related to the improper division of SFJ and side branches. Therefore, the inadequate surgical technique is the main responsible factor and neovascularization is never the only cause of recurrence [5]. Neovascularisation has an incidence of 7.1% after EVLT and 2.2% after RF ablation also. The responsible factors are the development of arteriovenous fistulae and the intensity of the inflammatory response for recanalization of ablated venous segments [3-5]. The findings about the greater saphenous vein (GSV) recanalization at the

More Information

***Address for Correspondence:** Fatih Islamoglu, Professor, Department of Cardiovascular Surgery, Medical Faculty, Ege University, İzmir, Turkey, Tel: 90 232 390 35 53; Email: fatih.islamoglu@ege.edu.tr; fislamoglu@hotmail.com

Submitted: 02 February 2020

Approved: 10 April 2020

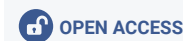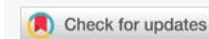Published: 13 April 2020

How to cite this article: Islamoglu F. Foam Sclerotherapy versus surgery in treatment of chronic venous disease. Arch Vas Med. 2020; 4: 005-007.

DOI: 10.29328/journal.avm.1001011

Copyright: © 2020 Islamoglu F. This is an open access article distributed under the Creative Commons Attribution License, which permits unrestricted use, distribution, and reproduction in any medium, provided the original work is properly cited.

Keywords: Venous; Varicose; Foam; Stripping; Ligation



SFJ have more commonly been found in patients undergoing RF ablation without ligation (46%) than RF ablation with ligation (14%) also support the importance of complete SFJ ligation [3-5]. It was found that surgery was not inferior to newer endovenous procedures in comparison of recurrence rates, overall complication rates, and symptom relief. Our results of former studies comparing the three different surgical techniques (complete stripping with HL, partial above-knee stripping with HL, and HL alone) have clearly shown that the best recurrence rate, best improvement in CEAP class, and best event-free survival rates are achieved using complete stripping with HL [6,7]. The rate of residual reflux and recurrence after partial stripping can reach up to 20%, as more often with patent below-knee saphenous veins than with incompetent perforatory veins (IPVs) undetected preoperatively. If these newer techniques can be described as theoretically equivalent to stripping with low ligation of the proximal saphenous vein, it is not wise or completely true to claim that their recurrence rates and effectiveness are better than those of classical complete stripping with HL. Past experiments have shown that, HL with complete division of the SFJ and all side branches, full-length obliteration of the saphenous vein is the best treatment choice to prevent recurrence [7].

After a technically correct surgery some factors, such as

an incompetent SFJ, an incompetent shorter saphenous vein (SSV), IPVs, an incompetent superficial vessel in the thigh, HL without stripping, female sex, and post-thrombotic deep venous insufficiency (DVI) were all associated with greater risk of recurrence [8]. My previous study on 372 patients showed that the predictors of early postoperative and later clinical status, outcome, and other events. preoperative CEAP class were bilateral limb disease, occupation, family history or genetic predisposition, prior deep vein thrombosis (DVT) (post-thrombotic etiology of varices), older age, and preoperative IPVs. The predictors of postoperative symptom recurrence and clinical and Doppler examination findings depend mostly on the preoperative clinical status of the patients and varicose vein surgery can prevent extension of venous reflux with 5-year symptom-free survival rate of 51 ± 0.8% [9].

We continued to recruit patients till today for this study and now it included 2986 and 4224 patients who had undergone classic stripping and foam sclerotherapy, respectively, within the previous 12 years (May 2005-May 2019). Preoperative and postoperative CEAP class, symptoms, recurrence, quality of life scores (venous class severity score-VCSS and Aberdeen varicose vein questionnaire score-AVVQ) and Doppler findings of the two groups were compared in 7210 patients, who had undergone either HL + stripping or HL + foam. Stripping group included 42% patients, foam + ligation group included 58% patients. The technique of operation has no significant effect on postoperative symptom recurrence, CEAP class, and doppler findings. There is no significant difference on postoperative effectivity between foam sclerotherapy and stripping (Figures 1,2). There is no significant difference on VCSS and AVVQ between two techniques (Table 1). Relative to other endovascular techniques such as laser and RF ablation, the use of foam sclerotherapy is significantly more cost effective. There is no significant difference in clinical important outcomes between ultrasound-guided foam sclerotherapy and endothermal ablation. As ultrasound-guided foam sclerotherapy is less expensive, it is likely to be a more cost-effective option in most patients in most healthcare settings [10]. Besides the ease of application, less postoperative discomfort and more patient satisfaction, a recent prospective study showed that although stripping of the GSV with HL were not associated with major discomfort and problems in the early postoperative period, SFJ ligation and GSV reverse foam sclerotherapy has better patient satisfaction with less postoperative bruising and discomfort and reduced analgesic requirements [11,12]. The safety and effectivity of ligation + foam sclerotherapy as an alternative

technique making possible daily surgery are not different than those of classic stripping. The predictors of postoperative symptom recurrence and clinical and Doppler examination findings depend mostly on the preoperative characteristics of individual patients and both varicose vein surgery and foam sclerotherapy with HL can prevent extension of venous reflux with time.

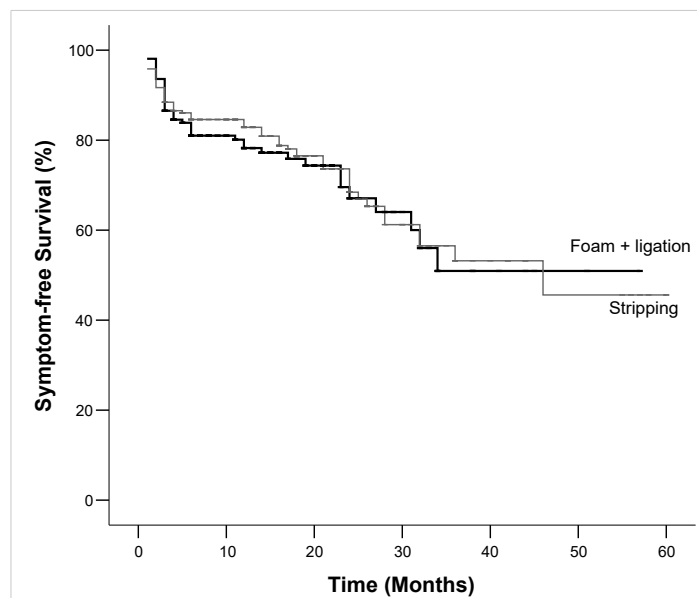


Figure 1: Comparative event-free survival rates: The 5-year symptom-free survival rates were 52% ± 0.6% and 47% ± 0.3% in the foam sclerotherapy and stripping groups, respectively, and there was no significant difference between stripping and foam+ligation groups, (Cox regression analysis: p = 0.692, risk ratio = 1.127, %95 confidence limits = 0.514 - 0.258).

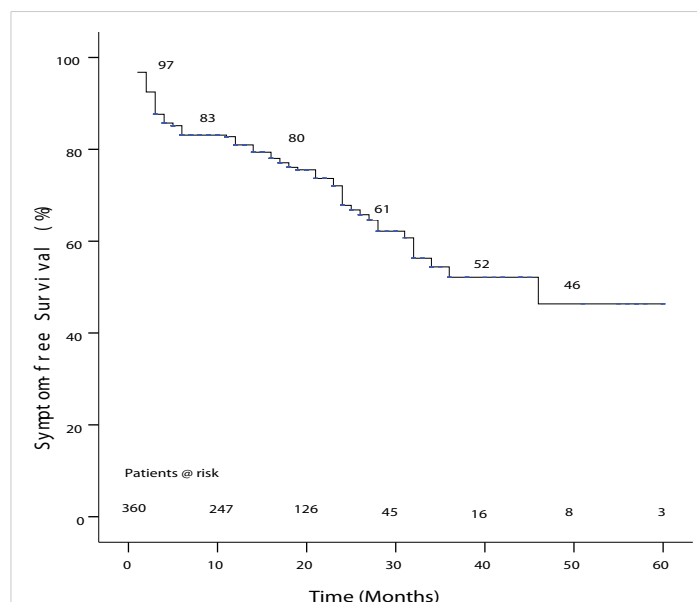


Figure 2: Actuarial event-free survival rate for all patients: symptom-free survival in 5 years, Kaplan-Meier analysis: % 46.3 ± 0.70.

Table 1: There is no significant difference on VCSS and AVVQ between two techniques.

	HL + Stripping		p	HL + Foam		p	p
	Preop.	Postop.		Preop.	Postop.		
Venous Clinical Severirty Score	5.9 ± 1.1	0.8 ± 0.8	0.017	5.7 ± 0.9	0.7 ± 0.6	0.023	0.721
Aberdeen Varicose Vein Questionnaire Score	19.6 ± 5.4	4.8 ± 1.4	0.031	18.7 ± 5.7	4.9 ± 1.3	0.038	0.664



References

1. Nicolaidis AN, Allegra C, Bergan J, Bradbury A, Cairols M, et al. Management of chronic venous disorders of the lower limbs: guidelines according to scientific evidence. *Int Angiol.* 2008; 27: 1-59.
PubMed: <https://www.ncbi.nlm.nih.gov/pubmed/18277340>
2. Eberhardt RT, Raffetto JD. Chronic venous insufficiency. *Circulation.* 2014; 130: 333-346.
3. Islamoglu F. Can varicose vein surgery prevent extension of venous reflux with time. *Medicographia.* 2016; 38: 193-194.
4. Merchant R, Pichot O. Long term outcomes of endovenous radiofrequency obliteration of saphenous reflux as a treatment for superficial venous insufficiency. *J Vasc Surg.* 2005; 42: 502-529.
5. Labropoulos N, Bhatti A, Leon L. Neovascularization after great saphenous vein ablation. *Eur J Vasc Endovasc Surg.* 2006; 31: 219-222.
6. Salles-Cunha SX, Comerota AJ, Tzilinis A. Ultrasound findings after radiofrequency ablation of the great saphenous vein. descriptive analysis. *J Vasc Surg.* 2004; 40: 1166-1173.
7. Dwerryhouse S, Davies B, Harradine K, Earnshaw JJ. Stripping the long saphenous vein reduces the rate of reoperation for recurrent varicose veins: five-year results of a randomized trial. *J Vasc Surg.* 1999; 29: 589-592.
8. Allegra C, Antignani PL, Carlizza A. Recurrent varicose veins following surgical treatment: our experience with five years follow-up. *Eur J Vasc Endovasc Surg.* 2007; 33: 751-756.
9. Islamoglu F. An alternative treatment for varicose veins: ligation plus foam sclerotherapy. *Dermatol Surg.* 2011; 37: 470-479.
10. Tan VKM, Tan SG. Technique and early results of ultrasound-guided foam sclerotherapy of the long saphenous vein for treatment of varicose veins. *Singapore Med J.* 2009; 50: 284.
PubMed: <https://www.ncbi.nlm.nih.gov/pubmed/19352572>
11. Abela R, Liamis A, Prionidis L. Reverse foam sclerotherapy of the great saphenous vein with sapheno-femoral ligation compared to standard and invagination stripping: a prospective clinical series. *Eur J Vasc Endovasc Surg.* 2008; 36: 485-490.
PubMed: <https://www.ncbi.nlm.nih.gov/pubmed/18718769>
12. Islamoglu F. Can foam sclerotherapy with high ligation prevent extension of venous reflux with time. *Ann Vasc Med.* 2018; 5: 1097.